

## Cannabis induced psychosis in patient with traumatic brain injury

Yadav J S<sup>1\*</sup>, Jain Shobhit<sup>2</sup>, K Arun<sup>3</sup>, Madhu<sup>4</sup>, Srivastava A S<sup>5</sup>

Dept. of Psychiatry, Institute of Medical Sciences, BHU, Varanasi

**\*Corresponding Author:**

**Yadav J S**

Dept. of Psychiatry, Institute of Medical Sciences, BHU, Varanasi

Email: jspsy@ipf.in

### Abstract

The association between TBI (traumatic brain injury) and psychosis remains a subject of debate and controversy. Differentiating patients with psychosis attributable to TBI and from patients with primary psychosis is difficult. Research has found that cannabis use prior to the age of 15 confers the greatest risk, due to the drug's effect upon the neurodevelopment processes occurring in the adolescent brain. In a study on heavy cannabis users demonstrated that significant dose-related hippocampal volume reductions, though in case of TBI reports varied with severity of TBI to trigger a psychosis in cannabis user. Some studies suggest that individuals who develop a psychosis after TBI had generally sustained moderate to severe head injuries.

In our case patient has long history of bilateral frontal lobe injury, although up to long time he was normal but when he started taking cannabis the symptoms of psychosis occurred. We have presumed that cannabis act as induction in development of psychosis in this case.

**Keywords:** Psychiatric disorders, Traumatic brain injury, Neuropsychiatry

### Introduction

Traumatic brain injuries (TBI) are a worldwide serious problem. It can causes immediate or long term problems, though there are limited knowledge about long term effect hence it has been named "silent epidemic." The memory and cognition problem may not immediate evident after TBI. It has been found that Injury to the brain has been implicated as a risk factor for the development of psychosis after many decades but there is very little systematic work in this direction<sup>(1)</sup>. In a study 0.07% and 9.8% of patients with TBI develop a post-traumatic schizophrenia-like psychosis, with prevalence rates increasing over time. He found that TBI increases the prevalence of schizophrenia by two to threefold over 10-20 years. Most of these patients did not have a family history of schizophrenia<sup>(2)</sup>. In a review data prevalence of post-traumatic schizophrenia was 0.7%. Men appear to be more frequently affected by post-head injury psychosis than women<sup>(3)</sup>. In a controversial study of appraised literature identify that the causal role of TBI in schizophrenia does not exist<sup>(4)</sup>. Though in our case study, we have found that the patient has long history of traumatic brain injury is high vulnerable for development of schizophrenia like symptoms after induction of cannabis use.

### Case

#### History of present illness

Mr. A eighteen year old young adult male brought in psychiatry OPD with complaints of cannabis use, disturbed sleep, Hearing of voice, fearfulness, abnormal agitated behaviour since three years with current exacerbation of symptoms for three months, episode

was second with fluctuating course. Patient started using bhang (swallowing form of cannabis) at age of fifteen year when he was studying in ninth standard. He started taking Bhang with his friend out of curiosity. He was told by his friends about appetite stimulating property of bhang and will make his built stronger. Considering this he started using bhang average dose single ball (about 50gms) two to three times a day regularly for ten days. He then shifted to Ganja (smoking form of cannabis) to get more high effects. He discontinued bhang and started smoking Ganja with his friend's average about two balls per day. After about one month of daily use of Ganja he started experiencing auditory hallucinations of his old childhood friend who died about ten years back. This voice would be of commenting and commanding type, He continued hearing voices at every two to three days interval, lasting for about ten to fifteen seconds, three to four times per day, more during night times. He quit the cannabis after treatment but even after two months of quitting Ganja, he developed symptoms as decreased need for sleep, elevated psychomotor activity, elated mood with intermittent lability, elevated self-esteem and authoritative. He would be found singing songs loudly and worshiping God "Bajarang Bali" excessively for about four to five hours per day. He developed ideas of grandiosity and would claim to own crores of rupees and often express his wishes to become richest person of the world. He also developed delusion of reference that people around him is talking about him due to which he would often become abusive and assaultive towards strangers. Auditory hallucinations also increased in frequency occurring about fifteen to twenty times a day, every day but more during night before

sleeping. After about fifteen days of onset of symptoms, he was advised Olanzapine 10 mg tablets by a psychiatrist. Gradually his symptoms improved completely within three months and he discontinued medications by himself, in about six months. He kept on experiencing hallucinations but less at previous frequency after one month stoppage of olanzapine. About one year later, at age of sixteen years he developed similar episode for two to three months which improved after same treatment and he discontinued treatment after six months. About one year later, at age seventeen years he restarted smoking ganja regularly average dose one ball per day. After four months of regular use he would experience that somebody holding his head from behind and turning around. He would also experience visual hallucination as black terrifying man with long hairs and red eyes trying to hit him with a bamboo stick. He would be agitated, fearful and assaultive in order to protect himself. Auditory hallucinations of his dead friend also increased in frequency and severity.

### Past history

Suggestive patient had traumatic brain injury at age of three year, after fall from terrace of his home while playing with his friends. After fall he developed approximately thirty minutes of unconsciousness and an open wound at frontal region of scalp. He underwent surgical repairing of wound and thereafter was doing well in his life.

### Investigations

The biochemical and systemic examination were within normal limit. His CT Scan Brain revealed old fracture of frontal bone with underlying bilateral frontal lobe involvement.

### Personal History

Birth history and early development was normal, He was an intelligent student, and his schooling performance was normal and would rank first in class till eight standards. His behaviour was good therefore often family member and others would appreciate him for his good behaviour. His parents were caring but many incidence not used interfere in his personal work because they would think that he will not do wrong. So they would often ignore him even when they found him with bad company.

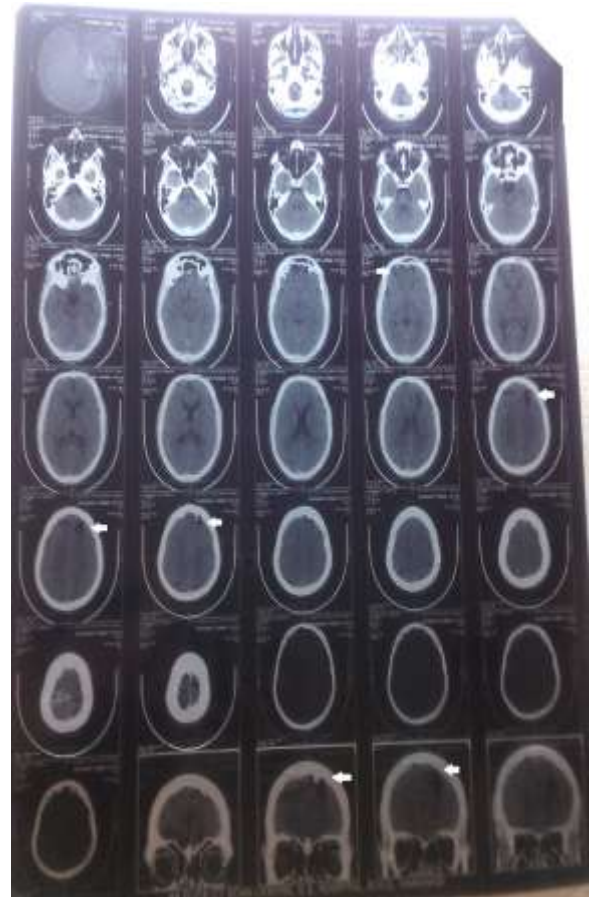
### Mental status examination

Psychomotor activities was increased, he was agitated has auditory hallucinations of his dead friend, delusion of made volition and somatic passivity.

### Treatment History

He was prescribed olanzapine 15mg per day in view of taking previous favourable response. He

stopped using cannabis and his symptoms completely remitted within three months of treatment.



### Discussion

In our study we found that patient developed commanding hallucination after one month of cannabis use, so he quit taking cannabis due to this problem. Again after quit up to six month his symptoms not subsided, rather developed additional symptoms of referential thinking and affective changes. For these problems when he took olanzapine most of the symptom subsided within six months of treatment but many important symptoms like agitation, commanding hallucinations again reappeared when patient left taking medicine. During this phase when patient restarted smoking cannabis he developed aggression and other symptoms of somatic passivity. Though patient shows frequent relapse with or without cannabis use hence we hypothesized that traumatic brain injury in childhood took important role in development of psychopathology. We have taken past two studies those support our hypothesis.

In a review of eight studies in those twenty year old brain injured service men taken the observational finding shows that the incidence of schizophrenia was two to three times higher than healthy cohort<sup>(2)</sup>.

In second study pre-existing head injury or a neurological condition were risk factors for developing a psychosis secondary to TBI<sup>(5)</sup>. We found that above two studies supported our hypothesis that traumatic brain injury could present schizophrenia like symptoms in later life. In a study based on cannabis use in-patient with schizophrenia WM (white matter changes) show that WM changes were mainly observed in the frontal and temporal areas, suggesting that dis connectivity in the left fronto-temporal area may contribute to the patho physiology of schizophrenia<sup>(6)</sup>. In addition, pathologic WM changes in this region may be an important step in the development of auditory hallucinations in schizophrenia. The further interesting finding in same brain area, of acute cannabis user patients showed reduced fractional anisotropy compared with healthy controls<sup>(7)</sup>. The overall finding suggested that severity of WM changes mainly in fronto-temporal area are relatively more vulnerable for development of severe psychotic symptom with cannabis use in those patients who have prior injuries of frontal brain area.

## Conclusion

Carrying out prospective studies through multivariate type analysis and developing prognostic models for psychiatric disorders associated to TBI are scientific immediate challenges. Such models should ideally contemplate clinical, demographic, biochemical, hormonal, neurochemical, neurosurgical, neuroimaging, and immunology variables. This approach will be successful only through an interdisciplinary work among researchers from the basic and clinical area.

## References

1. Fujii D, Ahmed I. Psychotic disorder following traumatic brain injury: a conceptual framework. *Cogn Neuropsychiatry* 2002;7(1):41-62.
2. Davison K, Bagley CR. Schizophrenia like psychoses associated with organic disorders of the central nervous system: a review of the literature. In: Herrington RN, ed. *British Journal of Psychiatry Special Publications* 1969;4:113-84.
3. Van Reekum R, Cohen T, Wong J. Can traumatic brain injury cause psychiatric disorders? *J Neuropsychiatry Clin Neurosci.* 2000;12(3):316-27.
4. David AS, Prince M. Psychosis following head injury: a critical review. *J Neurol Neurosurg Psychiatry* 2005;76:53-60.
5. De Mol J, Violon A, Brihaye J. Post-traumatic psychoses: a retrospective study of 18 cases. *J Archivo di Psychologia-Neurologia* 1987;48:336-50.
6. Seok JH, Park HJ, Chun JW, Lee SK, Cho HS, Kwon JS, Kim JJ. White matter abnormalities associated with auditory hallucinations in schizophrenia: A combined study of voxel-based analyses of diffusion tensor imaging and structural magnetic resonance imaging. *Psychiatry Res.* 2007;15:156(2):93-104.
7. Dekker N, Schmitz N, Peters BD, van Amelsvoort TA, Linszen DH, de Haan L. Cannabis use and callosal white matter structure and integrity in recent-onset schizophrenia. *Psychiatry Res.* 2010;30:181(1):51-6.