



## Case Report

# Is facial palsy in febrile phase of dengue similar to idiopathic Bell's palsy?

Sarvesh Chaudhary<sup>1\*</sup>, Rajarshi Chakraborty<sup>1\*</sup>

<sup>1</sup>Dept. of Neurology, King George's Medical University, Lucknow, Uttar Pradesh, India



## ARTICLE INFO

### Article history:

Received 08-05-2024

Accepted 21-06-2024

Available online 27-06-2024

### Keywords:

Facial palsy

Dengue fever

Bell's palsy

## ABSTRACT

In developing tropical countries, dengue infection is a serious vector-borne endemic disease. Neurological involvement in dengue fever can lead to a plethora of manifestations. Bell's palsy is an idiopathic inflammatory condition of the 7th cranial nerve. The association of Bell's palsy in dengue fever is scarcely reported in literature. In this case report, we tried to explore the diverse possibilities of acute-onset unilateral facial weakness in a 16-year-old male with a background of acute febrile illness with thrombocytopenia and transaminitis.

This is an Open Access (OA) journal, and articles are distributed under the terms of the [Creative Commons Attribution-NonCommercial-ShareAlike 4.0 License](https://creativecommons.org/licenses/by-nc-sa/4.0/), which allows others to remix, tweak, and build upon the work non-commercially, as long as appropriate credit is given and the new creations are licensed under the identical terms.

For reprints contact: [reprint@ipinnovative.com](mailto:reprint@ipinnovative.com)

## 1. Introduction

Dengue fever is a common vector-borne disease caused by flavivirus in tropical countries.<sup>1</sup> The pathophysiologic mechanism behind the involvement of nervous system in dengue infection can be either due to neurotropism (myositis, rhabdomyolysis, encephalitis, meningitis, and myelitis), systemic complications (encephalopathy and stroke) and post-infectious (acute disseminated encephalomyelitis, encephalomyelitis, myelitis, Guillain Barre Syndrome and neuropathies).<sup>2</sup> The association of facial palsy in dengue fever is not well documented. We illustrated a case of facial palsy in dengue fever with follow-up outcome. The interesting part is that Bell's palsy is an unusual presentation in febrile phase of dengue illness.

## 2. Case Description

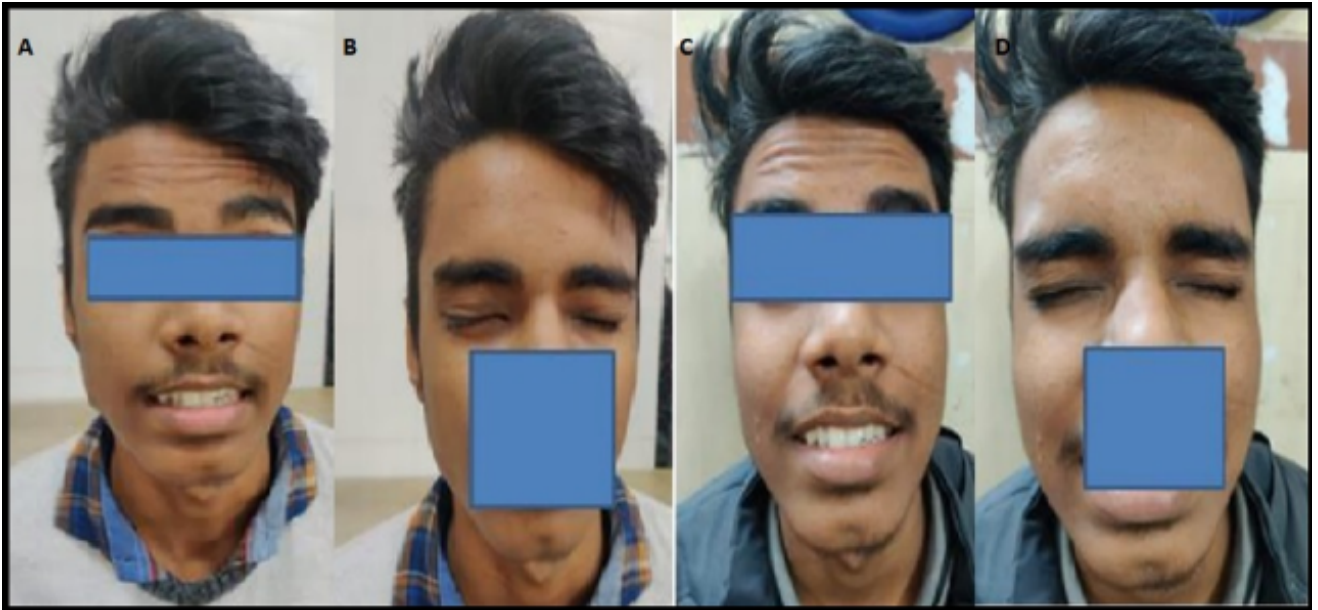A male in his sixteen presented with ongoing fever, headache, bodyache for 5 days followed by right-sided facial weakness in the form of drooping of angle of the mouth for 2 days. There was no history of any bleeding, rash

or joint pain. He had no history of associated ear ache, ear discharge, or weakness in any other part of the body. There was no history of cough, vomiting, convulsion, altered mentation, paresthesia, difficulty in swallowing or hearing, or any change in voice. There was no history of recent COVID-19 illness, diabetes mellitus, steroid usage, thyroid disease, tuberculosis, recent trauma or any similar illness in the past. On general examination, he was conscious, well oriented, febrile (temp 100 °F), blood pressure of 100/60 mm Hg, regular pulse of 102 beats/minute, with absence of pallor, clubbing, edema, lymphadenopathy or evidence of parotid enlargement. Nervous system examination showed normal higher mental function with right-sided partial lower motor neuron facial nerve palsy. (Figure 1A,B). Rest of neurological and other system examination were unremarkable.

His initial hemogram showed total white blood cell count of 4000/mm<sup>3</sup>, normal differential count, normal hemoglobin and platelet count of 0.75 lakh/mm<sup>3</sup>. He had elevated aspartate transaminase [120 International units/Litre(IU/L)] and Alanine transaminase levels [206 IU/L] and normal bilirubin levels. His renal function tests, electrolytes and blood sugar level were normal. His

\* Corresponding authors.

E-mail address: [satyalong@gmail.com](mailto:satyalong@gmail.com) (R. Chakraborty).



**Figure 1:** Initial presentation showing; (A): Reduced wrinkles on right forehead with right shallow nasolabial fold; (B): partial closure of right eye; with follow-up showing normal forehead wrinkling and nasolabial fold (C), and normal closure of eyes (D).

C-reactive protein was elevated (18 milligram/deciliter). His serological tests for malarial parasite, HIV, Hepatitis B, Hepatitis C were negative. Dengue serology showed positive NS1 antigen at day 3 and positive IgM at day 7 of fever-onset. With non-contrast computed tomography of head was normal. He was treated with short-course oral prednisolone therapy (omnacortil 40 mg/day once daily for 5 days with tapering dosage for next 5 days) and facial physiotherapy.

He came after 14 days for follow up, where he showed complete resolution of facial weakness along with laboratory improvement in the platelet count (1.26 lakh/cumm) and normal transaminase levels. (Figure 1 C,D).

### 3. Discussion

Young teen with facial weakness in view of fever, bodyache and thrombocytopenia, was thoroughly evaluated and diagnosed as Bells's palsy amidst dengue fever. The differentials included were Herpes infection, Varicella infection, COVID-19 infection related, HIV infection, Lyme's disease, Sarcoidosis. The element of fever, thrombocytopenia and transaminitis was the key pointer towards dengue illness was confirmed by IgM ELISA serology for dengue virus. A few studies have indicated a change in virological characteristics of dengue viruses.<sup>2,3</sup> The pathogenesis of isolated VIIIth nerve involvement in dengue infection is not well known. Immune-mediated neuronal damage could be possible hypothesis in dengue illness. Inflammatory marker like C reactive protein was

elevated in this patient further supporting the inflammatory nature of the disease. The early detection and initiation of corticosteroid therapy helped in early resolution of facial palsy like idiopathic Bell's palsy. The absence of structural lesion in this case showed a favorable prognosis. Bilateral facial palsy also reported in dengue, but in the post-febrile phase.<sup>4</sup> In this patient, we tried to highlight association of facial palsy with dengue in pyrexia phase which is rarely seen in literature.<sup>3,5</sup> Guillain barre syndrome (GBS) is another similar disorder which can be observed after dengue illness, wherein there can association of facial weakness.<sup>6</sup> A plethora of such immune-mediated disorders can be observed in dengue illness.<sup>7,8</sup> In a review by Garg et al., mononeuropathies and GBS were common neuropathies observed globally in dengue illness.<sup>9</sup> The rationale for the use of corticosteroids in acute phase of Bell's palsy is that inflammation and edema of the facial nerve are implicated in causing Bell's palsy and corticosteroids have a potent anti-inflammatory action which should minimise nerve damage and thereby improve the outcome.<sup>10</sup>

### 4. Conclusion

Bell's palsy is generally a post-infectious phenomenon observed in dengue infection. This case report emphasizes the para-infectious nature of presentation. The early detection and prompt use of corticosteroids in Bell's palsy in dengue has favourable outcome.

## 5. Learning Points

1. Dengue illness can have a plethora of neurological manifestations.
2. Unilateral Bell's palsy can occur rarely in febrile phase dengue illness.
3. Early detection and treatment with steroids is helpful.

## 6. Source of Funding

None.

## 7. Conflict of Interest


None.

## References

1. Murhekar MV, Kamaraj P, Kumar MS, Khan SA, Allam RR, Barde P, et al. Burden of dengue infection in India, 2017: a cross-sectional population based serosurvey. *Lancet Global Health*. 2019;7(8):e1065–73.
2. Solomon T, Dung NM, Vaughn DW, Kneen R, Thao LT, Raengsakulrach B, et al. Neurological manifestations of dengue infection. *Lancet*. 2000;355(9209):1053–9.
3. Peter S, Malhotra N, Peter P, Sood R. Isolated Bell's palsy - an unusual presentation of dengue infection. *Asian Pac J Trop Med*. 2013;6(1):82–4.
4. Khim NK, Loh WC, Rashid AM, Khan AH, Baharin J, Ibrahim A, et al. Bilateral facial nerve palsy: a rare post-dengue fever complication. *Egypt J Neurol*. 2022;58(1):1–4.
5. Sardana V, Bhattiprolu RK. Dengue Fever with Facial Palsy: A Rare Neurological Manifestation. *Ann Indian Acad Neurol*. 2019;22(4):517–9.
6. Ralapanawa DM, Kularatne SA, Jayalath WA. Guillain-Barre syndrome following dengue fever and literature review. *BMC Res Notes*. 2015;8:729. doi:10.1186/s13104-015-1672-0.
7. Verma R, Sahu R, Holla V. Neurological manifestations of dengue infection: a review. *J Neurol Sci*. 2014;346(1-2):26–34. doi:10.1016/j.jns.2014.08.044.
8. Carod-Artal FJ, Wichmann O, Farrar J, Gascon J. Neurological complications of dengue virus infection. *Lancet Neurol*. 2013;12(9):906–19.
9. Garg RK, Malhotra HS, Jain A, Malhotra KP. Dengue-associated neuromuscular complications. *Neurol India*. 2015;63(4):497–516.
10. Murthy JM, Saxena AB. Bell's palsy: Treatment guidelines. *Ann Indian Acad Neurol*. 2011;14(Suppl 1):570–2.

## Author biography

**Sarvesh Chaudhary**, Assistant Professor

**Rajarshi Chakraborty**, Assistant Professor  <https://orcid.org/0000-0003-2304-2177>

**Cite this article:** Chaudhary S, Chakraborty R. Is facial palsy in febrile phase of dengue similar to idiopathic Bell's palsy?. *IP Indian J Neurosci* 2024;10(2):111-113.