

Content available at: <https://www.ipinnovative.com/open-access-journals>

IP Indian Journal of Neurosciences

Journal homepage: <https://www.ijonline.org/>

Short Communication

Double seronegative myasthenia gravis but double positive - A case of LRP4/Agrin antibody positive myasthenia gravis

Somarajan Anandan^{1*}, Sajeesh S Rajendran², Jyothish P Kumar¹, Divine S Shajee¹, Sourav Asha Somarajan¹

¹Dept. of Neurology, St Joseph Hospital, Anchal, Kerala, India

²Dept. of Neurology, Welcare Hospital, Kochi, Kerala, India



ARTICLE INFO

Article history:

Received 25-02-2024

Accepted 09-04-2024

Available online 22-04-2024

This is an Open Access (OA) journal, and articles are distributed under the terms of the [Creative Commons Attribution-NonCommercial-ShareAlike 4.0 License](https://creativecommons.org/licenses/by-nc-sa/4.0/), which allows others to remix, tweak, and build upon the work non-commercially, as long as appropriate credit is given and the new creations are licensed under the identical terms.

For reprints contact: reprint@ipinnovative.com

Acquired myasthenia gravis (MG) is the most common disorder of the neuromuscular junction (NMJ) causing fatigable weakness of skeletal muscles. 80% percent of generalized myasthenia gravis (MG) patients are acetylcholine receptor antibody positive. Another 5-10% are positive for muscle specific tyrosine kinase (MuSK) antibodies. Double seropositive MG is very rare. Most of the double seronegative MG(DNMG) are due to an underlying autoimmune aetiology. New antibody targets in these DNMG patients are agrin, lipoprotein-receptor-related protein 4 (LRP4), acetylcholinesterase /collagen Q, anti-striational muscle [Titin, Kv1.4 potassium channel, and ryanodine receptors] and cortactin antigens at NMJ.¹ 15% of DNMG are positive for either agrin or low-density lipoprotein receptor-related protein 4 (LRP4) antibodies. 13% of DNMG patients have antibodies against both LRP4 and agrin (LAPMG). LRP4 is a receptor for agrin and forms LRP4-agrin complex, that binds and activates MuSK and promotes AChR clustering at NMJ. The presence of these autoantibodies was associated with a more severe generalised disease, but most patients respond to standard MG therapy. Here we describe a patient with DNMG who is positive for LRP4 and Agrin antibodies who responded very well to rituximab. Presence of agrin and LRP4 antibodies is

associated with a more severe disease course compared with DNMG, detection of these antibodies in these patients will help to prognosticate the disease and it is suggested to do anti-LRP4 and anti-agrin antibodies in all DNMG patients.²

A 47-year-old male presented to outpatient department with difficulty in lifting objects above the shoulder since few days. His upper limbs get fatigued easily. There was no h/o any pain or paraesthesia. He was more symptomatic on right side. There was no h/o any proximal or distal lower limb weakness. There was no h/o any diplopia, but noticed drooping of left eyelid for the past 5 days. There was no history of dysphagia, nasal twang to voice or head drop. Examination showed left partial ptosis improving with ice pack. There was left medial rectus palsy, bilateral triceps weakness and left biceps weakness. Other muscles in upper and lower limbs were normal (MGFA class IIA). There was no neck or trunk weakness. Deep tendon reflexes were normal. Sensory system was normal. Routine blood investigations including thyroid function tests were normal. Computerised Tomography chest did not show any thymic mass. Repetitive nerve stimulation at 3 Hz showed 23%, 10% and 21% decrement from left ulnar, left facial and right accessory nerves respectively. Acetyl choline receptor antibody and anti-MuSK antibody were negative. He was started on pyridostigmine and oral steroids with which he had partial improvement. Subsequently azathioprine

* Corresponding author.

E-mail address: drsomarajan@yahoo.co.in (S. Anandan).

was started 2mg/kg. On follow up he developed diplopia with bilateral medial rectus palsy and bilateral ptosis. His myasthenia gravis panel of antibodies showed positive anti-LRP4 antibody and anti-agrin antibody [Table 1]. He was given a single dose of rituximab 500 mg and is asymptomatic for the last 6 months.

Table 1:

Antibody	Result	Reference range
AChR antibody	<0.11nmol/L	<0.40 nmol/L
Anti-MuSK Ab	8.78 ng/ml	<84ng/ml
LRP4 Ab	95 ng/ml	<50 ng/ml
Agrin Ab	603 ng/ml	<153 ng/ml
Striational Ab	Negative	
Titin Ab	13ng/ml	<21.31 ng/ml
Ryanodine receptor Ab	533ng/ml	<596 ng/ml

Agrin is a proteoglycan released from the motor nerve terminal which binds to LRP4 and forms LRP4-agrin complex and activates MuSK resulting in AChR clustering at NMJ. Recruitment of Dok7 enhances MuSK dimerization and optimal activation of MuSK. [Figure 1] AChR clustering facilitates efficient signal transmission from motor neurons to muscle fibres leading to muscle contraction.³

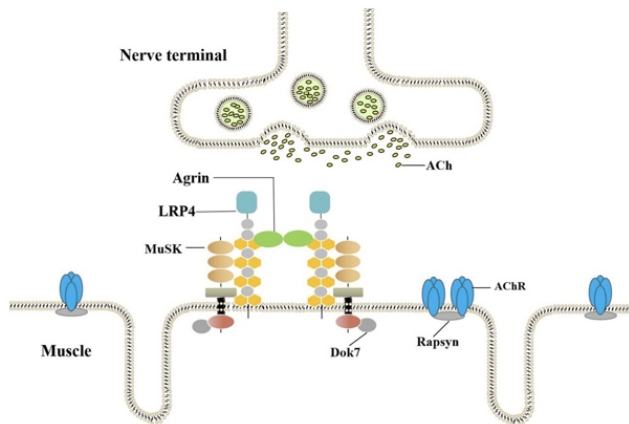


Figure 1: Agrin-LRP4-MuSK-Dok7 pathway for AChR clustering. Binding of agrin and LRP4 activates MuSK. Recruitment of Dok7 enhances MuSK dimerization resulting in optimal activation of MuSK resulting in AChR aggregation in post synaptic membrane.³

Anti LRP4 antibodies are seen in 2–50% of AChR and MuSK double seronegative patients.⁴LRP4 associated MG is more common in females (F:M ratio-2.5:1). LRP4 MG has a later age at onset, a milder clinical phenotype and variable thymus pathology.¹Study by Rivner et al demonstrated that LRP4 patients have a more severe presentation than quadruple seronegative MG (QNMG) (AChR Ab-, MuSK-, LRP4-, and Agrin) patients.²

Combined agrin and LRP4 antibody positive MG patients have more severe symptoms than isolated LRP4 MG. LRP4 antibodies have also been reported in disorders such as amyotrophic lateral sclerosis, polymyositis, multiple sclerosis and neuromyelitis optica.⁵

Up to 50% of triple seronegative MG patients (i.e., AChR Ab-, MuSK-, LRP4 -) have serum antibodies against agrin, which represents 2–3% of all MG patients.⁶ Agrin antibody positive MG usually occur in middle-aged or elderly men. These patients usually present with bulbar, ocular or limb muscle weakness. They may have associated thymoma. They have more severe phenotype and usually combination of prednisolone and pyridostigmine is effective.^{3,7}

Presence of anti-agrin antibodies in combination with antibodies against MuSK, LRP4, or AChR, suggests high incidence of autoantibodies against several neuromuscular proteins in the agrin-positive MG cases.⁷DNMG patients with both anti-LRP4 and anti agrin antibodies (LAPMG) patients are more likely to present as generalized MG. The mean age of onset is 46 years which is similar in LAPMG and QNMG groups.

In conclusion around 90% of generalized myasthenia gravis patients have either AChR antibody or anti-MuSK antibody. A good proportion of DNMG patients have antibodies to LRP4 and agrin. These patients have more severe disease compared to quadruple negative MG, but prognosis is favourable.


Conflict of Interest

None.

References

- Frykman H, Kumar P, Oger J. Immunopathology of Autoimmune Myasthenia Gravis: Implications for Improved Testing Algorithms and Treatment Strategies. *Front Neurol.* 2009;11:596621. doi:10.3389/fneur.2020.596621.
- Rivner MH, Quarles BM, Pan JX, Yu Z, Howard JF, Corse A, et al. Clinical features of LRP4/agrin-antibody-positive myasthenia gravis: A multicenter study. *Muscle Nerve.* 2020;62(3):333–43.
- Wang S, Yang H, Guo R, Wang L, Zhang Y, Lv J. Antibodies to full-length agrin protein in Chinese patients with myasthenia gravis. *Front Immunol.* 2021;12:753247.
- Pevzner A, Schoser B, Peters K, Cosma NC, Karakatsani A. Anti-LRP4 autoantibodies in AChR- and MuSK-antibody-negative myasthenia gravis. *J Neurol.* 2012;259(3):427–35.
- Behbehani R. Ocular Myasthenia Gravis: A Current Overview. *Eye Brain.* 2023;15:1–13. doi:10.2147/EB.S389629.
- Zhang B, Shen C, Bealmeas B, Ragheb S, Xiong WC. Autoantibodies to agrin in myasthenia gravis patients. *PLoS One.* 2014;9(3):91816. doi:10.1371/journal.pone.0091816.
- Gasperi C, Melms A, Schoser B, Zhang Y, Meltoranta J. Anti-agrin autoantibodies in myasthenia gravis. *Neurology.* 2014;82(22):1976–83.

Author biography

Somarajan Anandan, Consultant Neurologist  <https://orcid.org/0000-0002-7449-8468>

Sajeesh S Rajendran, Consultant Neurologist

Jyothish P Kumar, Resident

Divine S Shajee, Resident

Sourav Asha Somarajan, Resident

Cite this article: Anandan S, Rajendran SS, Kumar JP, Shajee DS, Somarajan SA. Double seronegative myasthenia gravis but double positive - A case of LRP4/Agrin antibody positive myasthenia gravis. *IP Indian J Neurosci* 2024;10(1):54-56.