



Case Report

Water jet injury to larynx & hypopharynx - A rare case report

Vidit R Shah¹, Santosh S Garag¹, Arunkumar J S^{1,*}, Shraddha Pai¹

¹Dept. of ENT, SDM College of Medical Sciences and Hospital, Shri Dharmasthala Manjunatheshwara University, Dharwad, Karnataka, India



ARTICLE INFO

Article history:

Received 16-02-2021

Accepted 26-02-2021

Available online 12-03-2021

Keywords:

Water jet injuries

Oropharynx

Debridement

Hoarseness

Microlaryngoscopy

ABSTRACT

High pressure injuries to the oral cavity and oropharynx, like water jets, are surgical emergencies. Such injuries are commonly reported while cleaning clogged pipes. This is a report of an adult male with water jet injury to larynx and hypopharynx. Based on the results of flexible laryngoscopy and contrast-enhanced CT, this case was managed with suspension microlaryngoscopy and extensive debridement of the necrosed tissue under general anesthesia. Following this, the patient recovered with minimal residual hoarseness which eventually resolved over six months.

© This is an open access article distributed under the terms of the Creative Commons Attribution License (<https://creativecommons.org/licenses/by/4.0/>) which permits unrestricted use, distribution, and reproduction in any medium, provided the original author and source are credited.

1. Introduction

Injuries from high-pressure water jet devices are surgical emergencies: the high velocity generated produces injuries that resemble the trauma caused by high-velocity missiles. These injuries show a unique pattern of extensive internal damage, often masked by trivial external evidence of injury.¹ The extent of damage from high-pressure injection injuries depends on a number of physical, chemical and biological factors, including the type, amount and velocity of injected material and the anatomical location of the injury.² We describe a rare case of high-pressure water jet injury to larynx & hypo pharynx, which was managed uneventfully.

2. Case Report

A 48 year old male diabetic patient presented to the ENT OPD with a history of progressive dysphagia, change in voice, neck swelling since 7 days and intermittent episodes of fever since 3 days. On inquiry patient revealed water jet

injury to the throat while attempting to clear a clogged pipe at his residence with pain and foreign body sensation in the throat immediately following injury. Patient had consulted a local practitioner for the above complaints but treatment with oral antibiotics showed no remission of symptoms.

At the time of presentation there was no stridor and the patient's oxygen saturation was 100% at room air, with a respiratory rate of 20/minute. Patient was febrile and associated with hoarseness of voice, on examination revealed an indurated swelling over the right side of the neck extending from the anterior border of the right sternocleidomastoid muscle anterosuperiorly, up to the hyoid bone inferiorly with restricted neck movements; there was no evidence of surgical emphysema. Indirect laryngoscopic examination showed slough like thick yellowish material in the right pyriform sinus, extending medially to involve the right ary-epiglottic fold & the right arytenoid. Both vocal cord movements were normal. There was evidence of right lateral pharyngeal wall cellulitis. Findings were confirmed with flexible laryngoscopy [Figure 1]. CT with contrast enhancement of the neck showed a heterogeneously enhancing hypo dense lesion in right pyriform sinus with thickening of ary-epiglottic fold [Figures 2 and 3],

* Corresponding author.

E-mail address: ctaarun@gmail.com (Arunkumar J S).

posterior and lateral pharyngeal wall with extension into the submandibular and parapharyngeal space multiple enlarged lymph nodes level II to IV. Patient was diabetic parameters were deranged with FBS 240 mg/dl, HBA1C: 9.7, PPBS: 358mg/dl.

Patient was treated with intravenous antibiotics and blood sugar levels controlled by taking physician opinion. Once the patient sugar levels are controlled patient was taken for suspension micro laryngoscopy under GA. Under the microscope surgical debridement of extensive slough over right supraglottic region and right pyriform fossa was done. No evidence of any dirt or foreign body was found at the debrided area on right supraglottic region and right pyriform fossa. Patient was discharged with complete remission of the neck swelling with minimal residual hoarseness which resolved over the next 6 months [Figure 4].

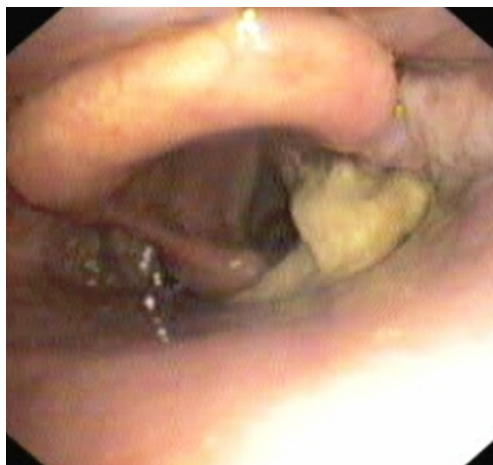

Fig. 1: Flexible endoscopy image

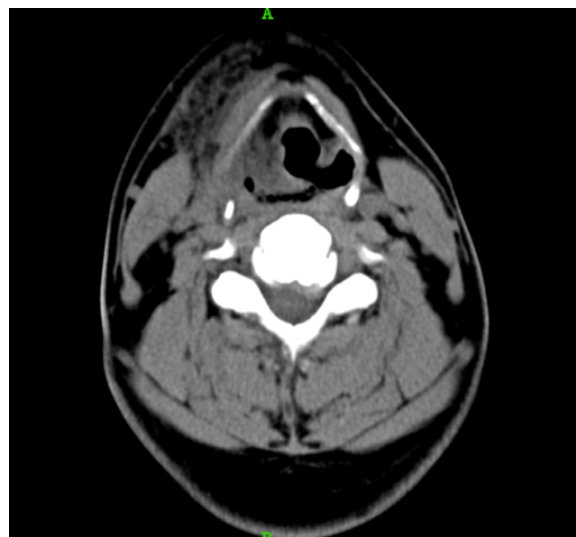


Fig. 2: CT scan image

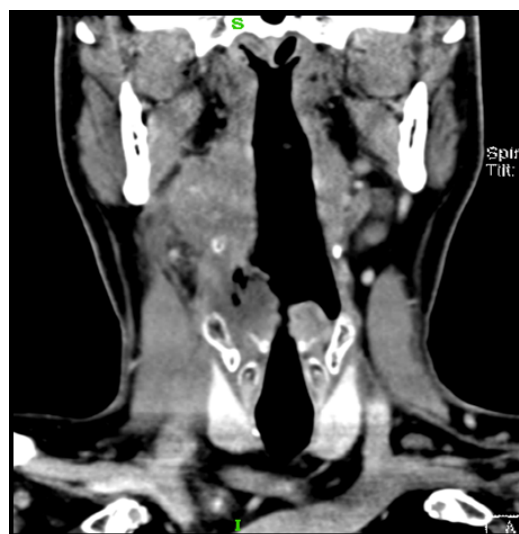

Fig. 3: CT image

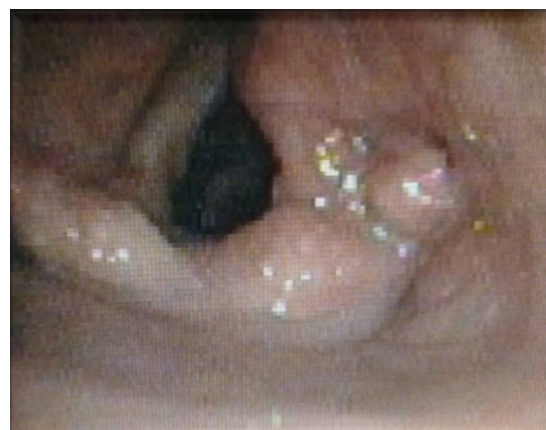

Fig. 4: Post treatment image

3. Discussion

Water jet injuries tend to show a common pattern of local morbidity.¹ Minimal external evidence of injury often masking extensive internal damage with infiltration of water and air into the tissue planes resulting significant sub mucosal injury. The primary injury is caused by the kinetic energy of the water jet.² Direct injury or thrombosis of blood vessels may result due to ischemia. The accompanying injection of bacteria and other micro-organisms, mucosal flora or contaminants in the water jet result in inflammation and abscess formation. A high index of suspicion is required when assessing patients with injuries from water jets.³ The presence of dysphagia, dysphonia or dyspnoea should alert the emergency physician to the possibility of impending airway obstruction.^{4,5} High pressure water jet injury to oropharynx resulted in peritonsillar abscess⁵ and needed intubation in some other case. A patient presenting with a history of a

direct hit in the mouth by a jet wash should be deemed to have impending airway obstruction, as this can evolve over several hours or even days if infection supervenes. Therefore, even if asymptomatic, these patients should be admitted for monitoring. Sometimes internal visceral injuries will not be evident immediately.⁶ Rapid evaluation and appropriate intervention, including protection of the airway, are required.

4. Source of Funding

No financial support was received for the work within this manuscript.

5. Conflict of Interest

The authors declare they have no conflict of interest.

References

- Ahmad M, Midwinter K, Capper R. High-pressure water jet injury to the pharynx, requiring intubation. *J Laryngology Otol.* 2006;120(7):600-1. doi:10.1017/s0022215106001162.
- Ramos JP, Carrison D, Phillips DL. Unusual vaginal laceration due to a high-pressure water jet. *West J Med.* 1998;169:171-2.
- David SK, Guarisco JL, Coulon RA. Pneumocephalus Secondary to a High-Pressure Water Injury to the Nose. *Arch Otolaryngol - Head Neck Surg.* 1990;116(12):1435-6. doi:10.1001/archotol.1990.01870120081014.
- Hagler SV, Sharma OP, Wadas JA. The dilemma of high-pressure water jet injuries. *Physician Assistant.* 2001;25:600-1.
- Fitzgerald C, Oosthuizen JC, O'dwyer T. A Case of Quinsy Following High-Pressure Water Jet Injury. *Iran Med J.* 2014;107(6).
- Redmond CE, McEvoy SH, Ryan ER, Hoti E. Pancreatic transection as a result of a high-pressure water jet injury. *BMJ Case Rep.* 2013;doi:10.1136/bcr-2013-200403.

Author biography

Vidit R Shah, Senior Resident

Santosh S Garag, Professor

Arunkumar J S, Professor and HOD

Shraddha Pai, Assistant Professor

Cite this article: Shah VR, Garag SS, Arunkumar J S, Pai S. Water jet injury to larynx & hypopharynx - A rare case report. *IP Indian J Neurosci* 2021;7(1):89-91.