

Endoscopic third ventriculostomy in post traumatic hydrocephalus- Institutional experience

Geover J. Lobo¹, Madhukar T. Nayak^{2,*}

¹Assistant Professor, ²Professor, Dept. of Neurosurgery, Fr. Muller Medical College & Hospital, Mangaluru, Karnataka, India

***Corresponding Author:**

Email: gonsalvessarita@gmail.com

Abstract

Introduction: Hydrocephalus is a known sequelae in traumatic brain injury patients. It may occur early or late and presents with dementia, urinary incontinence and difficulty in walking as described by Hakim and Adams. There are two distinct types of normal pressure hydrocephalus one is idiopathic most commonly seen in the elderly age groups and the other is secondary due to a cerebro vascular accident, trauma or surgery. The idiopathic type may not respond to the CSF diversion procedure, but the secondary type which responds to CSF diversion procedure. Our study aims at exploring the option of ETV in these patients not making them shunt dependent.

Materials and Methods: The patients with traumatic brain injury admitted in the dept. of neurosurgery between January 2012 and January 2018 were included into the study. Congenital hydrocephalus and secondary hydrocephalus due to spontaneous SAH and tumours were excluded. 14 patients were identified and if there was some improvement in their condition after CSF tap test were planned for endoscopic third ventriculostomy.

Results: Out of the 14 patients 2 were females and the remaining 12 were males. 2 did not improve at all. 12 had some improvement out of which 3 had a failure and underwent a v-p shunt. Hence there were 5 failures out of 14 which made 35.7%. Mitchel et al and Michelangelo et al reported 72-75% success rates in their study which is similar to our results.

Conclusion: ETV is an option which can be offered to patients with secondary hydrocephalus. The chances of failure though present the procedure is minimally invasive and improves CSF dynamics.

Keywords: Secondary hydrocephalus due to trauma, Endoscopic third ventriculostomy, Trauma induced hydrocephalus.

Introduction

Hydrocephalus is a known sequelae in traumatic brain injury patients. It may occur early or late and presents with dementia, urinary incontinence and difficulty in walking as described by Hakim and Adams.¹ Though Hakim described these symptoms for Normal Pressure Hydrocephalus (NPH), these are seen in post traumatic hydrocephalus as they are non obstructive or communicating hydrocephalus. Thus there are two distinct types of normal pressure hydrocephalus one is idiopathic most commonly seen in the elderly age groups and the other is secondary due to a cerebro vascular accident, trauma or surgery.^{2,3} Idiopathic may not respond to the CSF diversion procedure, 30-50% success rate unlike the secondary type which responds to CSF diversion having 50-70% success rate.^{4,5}

The etiology and pathophysiology has not been clearly understood but the thought that CSF drainage does not happen at the arachnoid villi is prevalent.⁶ In a patient presenting with Hakim's triad a suspicion of NPH has to lead to imaging studies. These imaging studies prove with images of dilated ventricles without atrophy and periventricular lucency the diagnosis of secondary NPH. A clinical CSF tap test based on the MMSE is done to predict the outcome of the planned treatment.^{7,8}

The treatment goal is to divert CSF reducing the progression of the symptoms and improving the

condition of the patient. The different CSF diversion procedures are V-P shunt, V-A Shunt and lately Endoscopic Third Ventriculostomy (ETV). ETV is contraindicated in Secondary Hydrocephalus is a known fact. Our study aims at exploring the option of ETV in these patients not making them shunt dependent.

Materials and Methods

The patients with traumatic brain injury admitted to the Department of Neurosurgery Fr Mullers Medical College were included in the study. The study was a prospective and a retrospective study from January 2012 to January 2018. Only the patients with a history of trauma and have developed hydrocephalus were included in the study. Children and hydrocephalus due to conditions like spontaneous SAH, tumors were not included. About 1480 patients were admitted for head injury during the study period out of which 171 were severe head injury. Only 14 out of the 171 developed hydrocephalus, which is an incidence of 8.1% (Fig. 1).

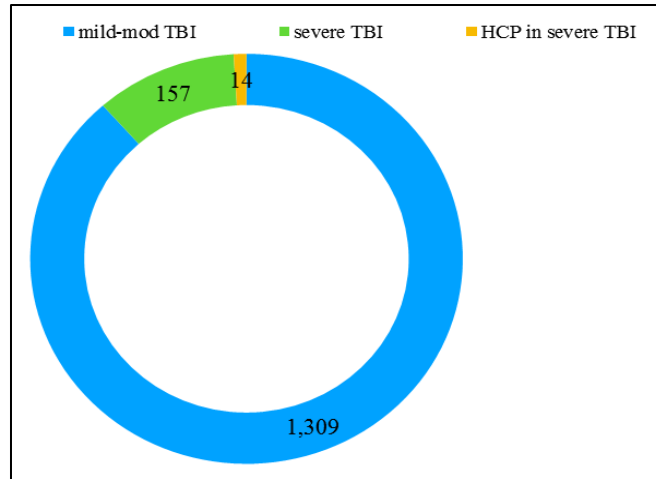


Fig. 1: Incidence of post traumatic Hydrocephalus

The global incidence of post traumatic hydrocephalus is 7-29%.^{9,10} A total of 14 patients were taken into study out of which 2 were females and 12 were males. (Table 1)

Table 1: Distribution between sexes

Total	Males	Females
14	12	2

The criteria to include these patients were the hydrocephalus with a past history of trauma, a CSF tap test showing improving MMSE scores, and radiologically no evidence of blood in the ventricles at the time of trauma and when they presented. Along with dilated ventricles with periventricular lucency (2). All the 14 patients went through the tap test where after consent a lumbar puncture was done at the L4- L5 level with a 18 gauge Lumbar puncture needle and minimum 50 ml CSF drained. An MMSE score before and after the tap was recorded. This procedure was done for 3 consecutive days. All the 14 patients had better MMSE scores at the end of the 3 days. These patients were then explained the procedure and its possible failure in detail and after their consent preparation for surgery was commenced.

A right Kocher’s point was taken as the surface marking a curved incision with a diameter of 3 cm and base towards the feeding temporal artery is done. A burr hole is placed at the predetermined point. Dura mater is cauterized and opened. With a brain cannula the ventricle is tapped, the sheath of the neuroendoscope is introduced. Once the obturator is removed a 0 degree scope is introduced into the sheath. The normal anatomy of the Foramen of Munroe is appreciated. Most commonly it will be wide enough to accommodate the scope, which is advanced into the third ventricle. The floor of the third ventricle is inspected and the membrane anterior to the mammillary bodies is perforated with a 5 F Fogarty catheter and

widened. The scope is used to see if any persisting membrane or webs are present, the intact pulsating basilar artery and its perforators and the flapping floor of the third ventricle. Complete homeostasis is confirmed and closure done in layers.

Results

There were no intra op events hence all the 14 patients survived. 8 (57.1%) of the 14 improved in their gait. They were ambulant with support. 10(71.4%) improved in their dementia but only 4(28.5%) improved from their urinary incontinence. 2 did not improve at all. 3 patients had a sudden collapse a CT brain showed acute hydrocephalus and underwent V-P shunt after which they improved only in gait but persisted to have dementia and urinary incontinence (Fig. 2). Improvement in the condition of the patients varied from 1-4 weeks.

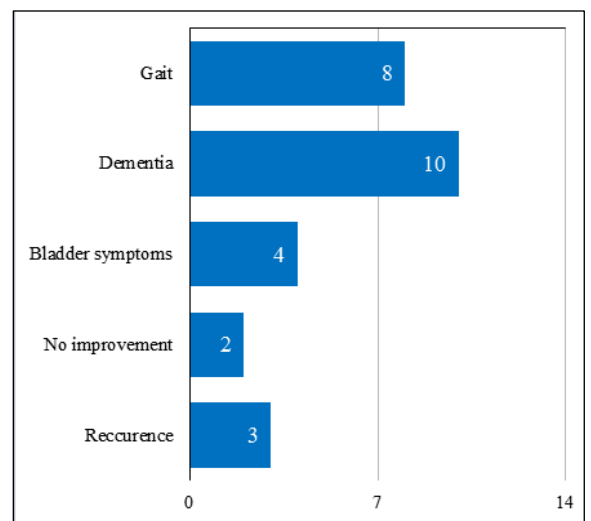


Fig. 2: Graphic representation of the results

Table 2: Summary of the results

Summary of the Results	
Total (n)	14
Gait improvement	8(57.1%)
Dementia improvement	10 (71.4%)
Bladder symptom improvement	4 (28.5%)
No improvement (a)	2 (14.2%)
Recurrence (b)	3 (21.4%)
Failure (a+b)	5 (35.7%)

Post procedure an observation period of one week was considered, those who did not improve after one week were considered a failure. Those in whom a V-P shunt had to be put were also considered a failure as the endoscopic procedure did not help them in their condition. Hence there were a total of 5 failures out of 14 patients making the percentage of failure 35.7%.

Discussion

Hydrocephalus secondary to trauma is a communicating type which has presenting features similar to Normal Pressure Hydrocephalus. There are many theories on the pathophysiology of NPH but in secondary hydrocephalus the insult of the trauma causes decreased capacitance of the ventricles and also decreasing the flow of CSF in its pathway. Blood products could be the cause of blocking draining channels. Koto et al and Krauss et al in their studies have documented that the stretching of the ventricle due to hydrocephalus causes vascular compromise, local ischaemia and due to the decreased compliance the pulse pressure increases causing local barotrauma in the ventricle wall.^{11,12} Hence the acetazolamide challenge test is a failure as it does not increase the cerebral blood flow.¹³ While V-P shunt causes an increased capacitance and modulates the CSF pulse pressure, thereby causing decreased ischaemia increased perfusion.¹⁴

Though the standard treatment for secondary hydrocephalus is V-P shunting increasing number of neurosurgeons are opting for ETV as it is minimally invasive and forms a cisternal draining channel. In our study the patients selected sustained a severe traumatic brain injury but did not have blood in the ventricles at the time of trauma and on presentation with symptoms. The percentage of failure with ETV in our study is 35.7% which is not a large number as the rest had some improvement even after 4 weeks. ETV causes a reversal of the flow from the draining channels and increased turbulence through the basal cisterns. It also proves that there is some brain compliance and only a partial outlet obstruction.¹⁵ Mitchell et al and Michelangelo G et al reported an improvement of 72-75% in their studies.^{14,15} This coincides with our results too. Michelangelo went on to state that the improvement in patients with ETV is due to improved CSF dynamics at a early stage hence reducing the trauma to the periventricular

parenchyma.¹⁵ A study from the cochrane database by Tudor K et al reports no advantage or improvement after ETV and majority of the patients had to undergo other CSF diversion procedures.¹⁶ In his study Balevi notes that ETV improved the symptoms of head ache, gait disturbance and urinary incontinence but not dementia secondary NPH patients, further he mentions that ETV can be successful if done in selected patients.¹⁷

Conclusion

Endoscopic third ventriculostomy is an option, which can be offered to patients with secondary hydrocephalus due to trauma. In carefully selected patients like the criteria we used ETV can give good results, though the failure and alternate procedure has to be kept in mind. Ours is a small number as ETV was offered to a selected few patients with post traumatic hydrocephalus.

References

1. Adams RD, Fisher CM, Hakim S, et al. Symptomatic occult hydrocephalus with "normal" cerebrospinal pressures: A treatable syndrome. *N Engl J Med* 1965;273:117.
2. Mohammed Ahmed Eshra. Endoscopic third ventriculostomy in idiopathic normal pressure hydrocephalus. *Alexandria Journal of Medicine* (2014) 50, 341–344.
3. National Institute of Neurological Disorders and Stroke, 2011. NINDS Normal Pressure Hydrocephalus Information Page.
4. Vanneste JAL, Augustijn P, Dirven C, Tan WF, Goedhart ZD. Shunting normal pressure hydrocephalus: do the benefits outweigh the risks? A multicenter study and literature review. *Neurology* 1992;42:54-59.
5. Vanneste JAL. Three decades of normal pressure hydrocephalus: are we wiser now? *J Neurol Neurosurg Psychiatry* 1994;57:1021-1025.
6. Bradley WG. Normal pressure hydrocephalus: new concepts on etiology and diagnosis. *AJNR Am J Neuroradiol.* 2000 Oct;21(9):1586-90.
7. Wood JH, Bartlett D, James AE, Udvarhelyi GB. Normal-pressure hydrocephalus: diagnosis and patient selection for shunt surgery. *Neurology* 1974;24:517-525.
8. Wikkelso C, Andersson H, Blomstrand C, Lindqvist G. The clinical effect of lumbar puncture in normal pressure hydrocephalus. *J Neurol Neurosurg Psychiatry* 1982; 45:64-69.
9. Choi I, Park HK, Chang JC, Cho SJ, Choi SK, Byun BJ. Clinical factors for the development of posttraumatic hydrocephalus after decompressive craniectomy. *J Korean Neurosurgery Soc.* 2008;43:227–231.
10. Kumar, A., Kumar, P., Jaiswal, G., et al. Posttraumatic hydrocephalus: Lessons learned from management and evaluation at a tertiary institute with review of literature. *Romanian Neurosurgery* 2017, 31(3), pp. 356-363.
11. A. Koto, G. Rosenberg, L.H. Zingesser, D. Horoupian, R. Katzman Syndrome of normal pressure hydrocephalus: possible relation to hypertensive and arteriosclerotic vasculopathy *J Neurol Neurosurg Psychiatry*, 40 (1977), pp. 73-79.
12. J.K. Krauss, J.P. Regel, W. Vach, D.W. Droste, J.J. Borremans, T. Mergner Vascular risk factors and

- arteriosclerotic disease in idiopathic normal pressure hydrocephalus of the elderly *Stroke*, 27 (1996), pp. 24-29.
13. H. Miyake, T. Ohta, Y. Kajimoto, J. Deguchi. Diamox challenge test to decide indications for cerebrospinal fluid shunting in normal pressure hydrocephalus *Acta Neurochir*, 141 (1999), pp. 1187-1193.
 14. P. Mitchell, B. Mathew. Third ventriculostomy in normal pressure hydrocephalus. *Br J Neurosurg*, 13 (1999), pp. 382-385.
 15. Gangemi Michelangelo. Endoscopic third ventriculostomy in idiopathic normal pressure hydrocephalus *Neurosurgery*, 55 (2004), pp. 129-134.
 16. Tudor K, Tudor M, McCleery J, Car J. Endoscopic third ventriculostomy (ETV) for idiopathic normal pressure hydrocephalus (iNPH). *Cochrane Database of Systematic Reviews* 2015, Issue 7. Art. No.:CD010033.
 17. Balevi M. Endoscopic third ventriculostomy in normal pressure hydrocephalus and symptomatic long-standing overt ventriculomegaly. *Asian J Neurosurg* 2017;12:605-12.