

## Sciatic neuropathy following intramuscular injection: Clinical and electrophysiological findings

Tarun Kumar Ralot<sup>1,\*</sup>, Jatin Choudhary<sup>2</sup>, Nikhil Arvind Dongre<sup>3</sup>, Vinod Kumar<sup>4</sup>, Dharmendra Meena<sup>5</sup>

<sup>1</sup>Assistant Professor, <sup>2,3,4,5</sup>Resident Doctor, <sup>1</sup>Dept. of Neurology, <sup>2,3,4,5</sup>Dept. of Medicine, R. N. T. Medical College, Udaipur, Rajasthan, India

**\*Corresponding Author:**

Email: drtarun98@gmail.com

### Abstract

**Introduction:** Post injection sciatic neuropathy is very common in developing country like India and mostly it is because of faulty technique and injecting substances. Due to thin fat pad and less muscle bulk of buttocks in children, it makes them more prone to sciatic nerve injury than adults.

**Objective:** The aim of this study was to evaluate clinical and electrophysiological findings of post-injection sciatic neuropathy.

**Materials and Methods:** We included 30 consecutive patients who had history of intragluteal injection and subsequently developed neuropathy and their clinical and electrophysiological examination was done.

**Results:** The most affected nerve was Sural Nerve (83.33%) while Superficial Peroneal nerve was least affected (16.67%). Fifteen cases had both Tibial and Peroneal nerve affection. Cases who had both sensory motor axonal neuropathy were twenty seven while one case exclusively had motor axonal neuropathy. One case exclusively showed pure sensory neuropathy. Demyelinating neuropathy was found in one case.

**Conclusion:** The sciatic neuropathy is a common health problem in children after injection so, intramuscular injection is better avoided in children. Bilateral involvement in eight cases hints that there are some more mechanisms involved in neuropathy other than local injury.

**Keyword:** Sciatic Neuropathy, Intramuscular Injection, Electrophysiological.

### Introduction

Sciatic nerve injury is an iatrogenic and rare complication of intragluteal injections. Light paresthesia to more severe sensory disturbances, pain and muscular paralysis can be its neurological sequelae. It has been shown in various studies that intraneural injection is one of the main and frequent reason for injection related nerves injuries.<sup>(1,2)</sup>

Due to thin fat pad and less muscle bulk of buttocks in children, it makes them more prone to sciatic nerve injury than adults. Injection direction and the nature of the injected substance is also a responsible factor.<sup>(3)</sup> It has been shown that antibiotics and analgesics are most frequent offenders.<sup>(4)</sup>

### Aims and Objectives

The aim of this study is to evaluate clinical and electrophysiological findings of post-injection sciatic neuropathy. This study was undertaken at Department of Neurology, R.N.T. Medical college and attached group of Hospitals, Udaipur, Rajasthan.

### Material and Methods

Age, gender, clinical and electrophysiological features of thirty cases, who were sent to our laboratory between 2013-2016 were studied.

They were evaluated by conventional nerve conduction study and needle electromyography.

The study design was cross-sectional study.

### Selection Criteria

#### Inclusion:

1. Patients having history of light paresthesias to more severe sensory disturbances, pain and muscular paralysis followed by an intramuscular injection.
2. Patients of either gender.
3. Those undergoing electromyography and consenting for the participation in this study.

#### Exclusion:

1. Negative ENMG findings,
2. Patients having polyneuropathy including in the lower extremities
3. Patients having lumbosacral radiculopathy at L4, L5 and S1 levels.
4. Patients having severe lower extremity edema.
5. Patients having a diagnosis of polyneuropathy, radiculopathy or lumbosacral plexopathy, made through history, neurological findings and ENMG findings.

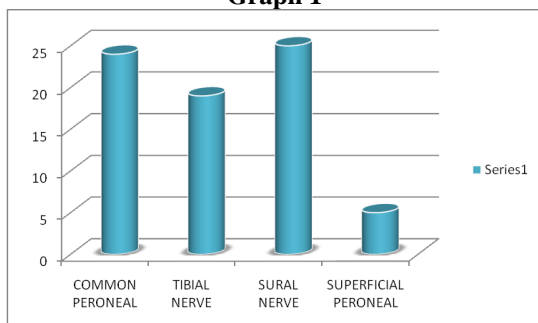
### Procedure

As the first step a history of injection was taken from every patient. The neurological examination consisted of motor, sensory and reflex examinations. The sensory examination consisted of routine testing of touch, pain and vibration sensation. Motor deficits were documented for each of the lower limbs. A routine sciatic nerve injury ENMG protocol was administered to every patient.

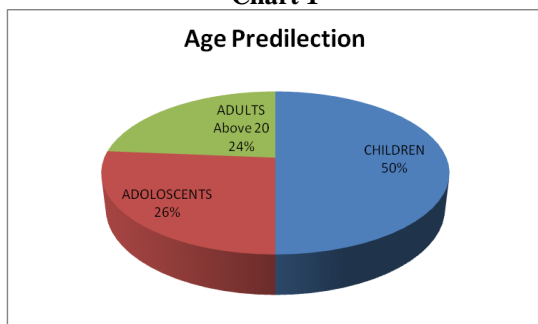
## Results

The study included 30 patients aged between 1-60 years and 50% of the cases were children (between 1-9 years) and 26.67% were adolescents (between 10-19 years). All electrophysiological examinations were done between one week to six weeks duration after the injection. Bilateral involvement was seen in eight cases. The most affected nerve was Sural Nerve (83.33%) while Superficial Peroneal nerve was least affected (16.67%). Fifteen cases had both Tibial and Peroneal nerve affection. Cases who had both sensory motor axonal neuropathy were twenty seven while one case exclusively had motor axonal neuropathy. One case exclusively showed pure sensory neuropathy. Demyelinating neuropathy was found in one case.

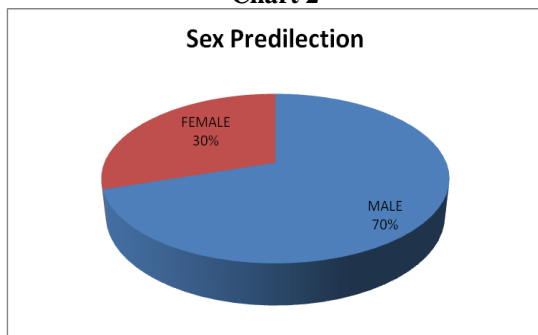
**Graph 1**



**Chart 1**



**Chart 2**



## Discussion

In this study, we investigated sciatic nerve injury due to intramuscular injection of the patients. We found that most of the patients had moderate or severe

lesions, and their recovery was minimal. The degree of postinjection sciatic nerve injury varies from sensory disorders to severe motor disorder. In the literature, most of the patients had partial involvement, and although the level of recovery depends on the severity of the lesion, most of the patients had minimal recovery.<sup>(8,11,12)</sup> In this study, bilateral involvement was seen in eight cases while demyelinating neuropathy was found in one case. In those cases, we have extensively worked up for other causes of neuropathy like vitamin B12, Blood sugar to evaluate for Diabetes, HIV, Guillain barre syndrome (CSF studies to rule out albumin cytological dissociation and cellularity), ANA and Vasculitis profile.

In the literature, many case reports or case series have been written about this issue, but most of them are about children.<sup>(1,6,8-10)</sup> Mishra<sup>(10)</sup> reported that 80% of patients were affected in childhood. The present study also supports the report as majority of patients were children. In addition, studies have shown that men have a higher risk of injury than women because of a thinner fat pad.<sup>(2,5,6,11)</sup> Our findings support this hypothesis because 70% of our patients were male. Studies also have shown that the common peroneal nerve is more affected because of its posterolateral position and smaller amount of supporting connective tissue.<sup>(8,11)</sup> In our study, the sural component is more involved in sensory part while in motor Common Peroneal is more involved than Tibial which is in concordance with the older studies.

Some drugs, especially analgesics and antibiotics, have often been reported as the cause because of their frequent use. Sevim et al.<sup>11</sup> also reported that the drugs metamizole and cefazolin were responsible for injury. Most of our patients did not know the name of the injected drug, but 25 patients reported they had been injected with analgesics and 5 patient reported an antibiotic injection. It has been reported that BMI might be an etiological factor for injury because patients with a low BMI have thinner pad tissue.<sup>(2,11)</sup> In our study group, most of the patients had a low BMI. It is recommended that rational and judicious use of injections should be considered in children and gluteal site for intramuscular injections should be universally discarded to prevent serious problem of sciatic nerve injury.

## Conclusions

Our findings indicate that sciatic injection neuropathy is a common health problem in children so, intramuscular injection is better avoided in children. Bilateral involvement in eight cases hints that there are some more mechanisms involved in neuropathy other than local injury. One case showed demyelinating neuropathy which compels us to evaluate potential of intramuscular injection as an immune stimulus. Special attention should be paid to educating the medical personnel on the safe injection techniques.

### Acknowledgements

We are very thankful to Mr Yogesh Sukhwal, ENMG Laboratory Technician who helped us for maintaining records and aided us in this important study.

### References

1. Villajero FC, Pascual AM. Injection injury of the sciatic nerve. *Child's Nerv Syst.* 1993;9:229-232.
2. Akyüz M, Turhan N. Postinjection sciatic neuropathy in adults. *Clinical Neurophysiology.* 2006;117:1633-1635.
3. Hudson AR. Nerve injection injuries. *Clinics in Plastic Surgery.* 1984;11:27-30
4. Brown BA. Sciatic injection neuropathy. *Calif Med.* 1972;116:13
5. Bramhall RJ, Deveraj VS. Traumatic sciatic nerve palsy after gluteal injection. *Eur J Plast Surg* 2011; 34: 137-8.
6. Yeremeyeva E, Kline DG, Kim DH. Iatrogenic sciatic nerve injuries at buttock and thigh levels: the Louisiana State University Experience Review. *Neurosurgery* 2009;65:A63-6.
7. Fapojuwo OA, Akinlade TS, Gbiri CA. A three-year review of sciatic nerve injection palsy in the Physiotherapy Department of a Nigerian Specialist Hospital. *Afr J Med Med Sci* 2008;37:389-93.
8. Maqbool W, Sheikh S, Ahmed A. Clinical, electrophysiological, and prognostic study of postinjection sciatic nerve injury: an avoidable cause of loss of limb in the peripheral medical service. *Ann Indian Acad Neurol* 2009;12:116-9.
9. Sitati FC, Naddumba E, Beyeza T. Injection induced sciatic nerve injury in Ugandan children. *Trop Doct* 2010;40:223-4 (abstract).
10. Mishra P, Stringer MD. Sciatic nerve injury from intramuscular injection: a persistent and global problem. *Int J Clin Pract* 2010;64:1573-19.
11. Sevim S, Kaleagasi H. Sciatic injection injuries in adults: is dipyron a foe to nerve. *Acta Neurol Belg* 2009;109:210-3.
12. Pandian JD, Bose S, Daniel V, Singh Y, Abraham AP. Nerve injuries following intramuscular injections: a clinical and neurophysiological study from Northwest India. *J Peripher Nerv Syst* 2006;11:165-71.