

## Intracranial ganglioglioma: A rare case report

S Varun Kumar<sup>1\*</sup>, K Srinivas Rao<sup>2</sup>, Lalitha Kundumula<sup>3</sup>, Sayed Ameer Basha<sup>4</sup>

<sup>1</sup>Resident, <sup>2</sup>Senior Consultant, <sup>3</sup>Registrar, Dept. of <sup>2</sup>Radiation Oncologist, Yashoda Hospital, Secunderabad, Telangana, <sup>4</sup>Consultant, Dept. of Neuro Surgeon, Care Hospital, Hyderabad

**\*Corresponding Author:**

E-mail: drsvarunkumar@gmail.com

### Abstract

Gangliogliomas are considered rare tumors which account for 0.4-0.9% of intracranial neoplasms. The peak of its incidence occurs between 10 and 20 years of age. These tumors are composed of glial and ganglion cells and they are relatively low grade neoplasms associated with good prognosis. We report a rare case of intracranial ganglioglioma in a 10 year old boy who underwent surgery and adjuvant radiotherapy.

**Keywords:** Adjuvant radiotherapy, Gangliogliomas, Glial, Ganglion cells, Intracranial neoplasms.

### Introduction

Ganglioglioma is a rare neuroepithelial tumor of the central nervous system (CNS)<sup>(1)</sup> which makes up 0.4-0.9% of all brain tumors in adults and 1% of those in children<sup>(2)</sup>. Most patients are younger than 30 years old, while the age span varies from 2 months to 70 years<sup>(3)</sup>. These tumors are known to be accepted as low grade, presenting with intractable seizures with an incidence of 75-100% and the temporal lobe is the most common location<sup>(4)</sup>. First treatment of choice is surgery in general<sup>(4)</sup>, however radiotherapy is generally considered in case of an incomplete resection or recurrent tumors<sup>(5)</sup>.

### Case History

A 10 year old boy presented to the hospital with 3 to 5 episodes of seizures daily since 15 days associated with mild headache and vomiting. No significant past or family history noted. On examination patient is conscious and coherent to time, place and person. No neurological deficits noted. On radiological evaluation MRI brain was carried out which showed a well defined solid appearing lesion noted in the medial aspect of the temporal lobe. It measures about 2.5\*2.6\*3.5cm. The lesion is displacing the left hippocampus anterosuperiorly and projecting into the temporal horn of left lateral ventricle (Fig. 1). Patient underwent left parietal craniotomy with excision of tumor. On histopathological examination dysplastic neurons intermixed with glial astrocytic component noted. Glial component is highlighted by GFAP antibody on immunohistochemistry stain and neuronal component is highlighted by chromogranin B. MIB1 index less than 1 to 2% in glial and neuronal component thus diagnosis of Ganglioglioma, WHO grade 1 was rendered (Fig. 2,3,4). Post-operative CT scan revealed a residual lesion in the left hippocampal region with peripheral

calcification (Fig. 5). Received radiotherapy to the residual lesion to a dose of 54GY in 30 fractions.

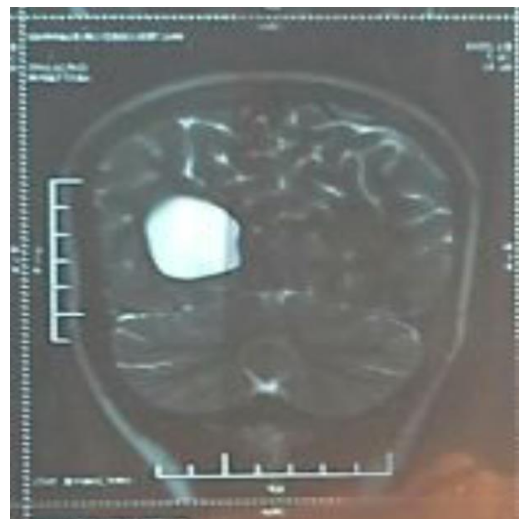


Fig. 1

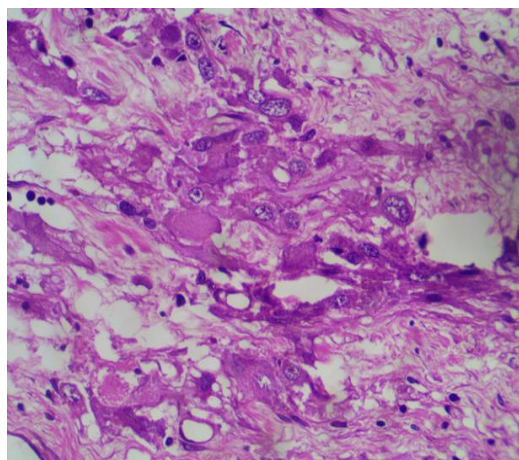


Fig. 2

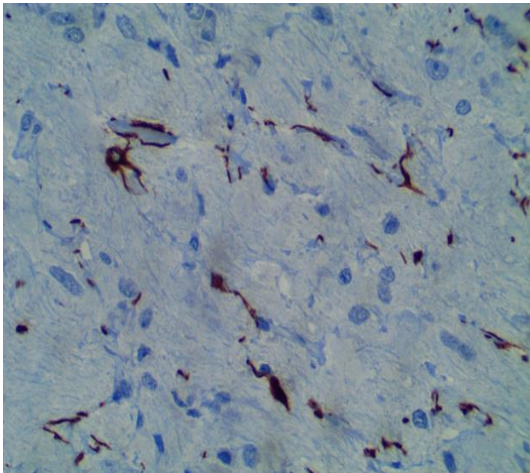


Fig. 3

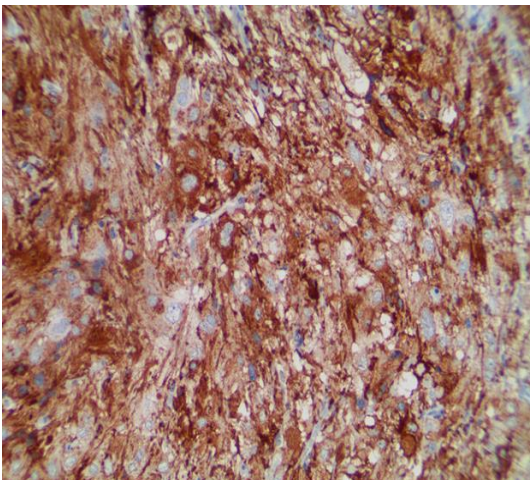


Fig. 4

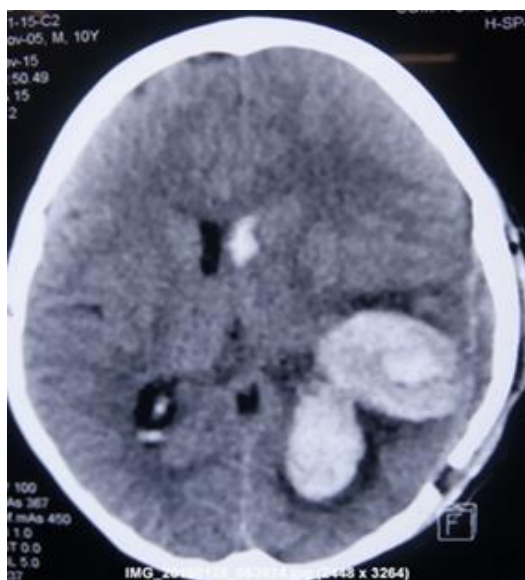

Fig. 5

## Discussion

Gangliogliomas are tumors of low malignancy and slow growth with long clinical history<sup>(3)</sup>. Most are macroscopically well-circumscribed and are commonly located in the temporal lobe, followed by frontal lobe and less frequently ventricular regions, thalamus and hypothalamus, parietal and occipital lobes<sup>(4)</sup>. Clinically, the most common presenting symptom is seizures, with an incidence rate of 75-100% in the literature<sup>(1)</sup>.

Radiologically, ganglioglioma is frequently cystic and calcified. Contrast enhancement may be seen with computerized tomography (CT) and magnetic resonance imaging (MRI); while solid and anaplastic subtypes can demonstrate even better contrast enhancement<sup>(4)</sup>. But, there is still no unique appearance on CT and MRI scans. Our case generally demonstrated a cystic appearance on radiologic examination with mild to moderate contrast enhancement on both CT and MRI scans without any characteristic definitive sign.

Gangliogliomas are histologically comprised of neuronal and glial elements. Glial component could include anaplastic degeneration<sup>(7)</sup>. The neuronal element has been reported to be comprised of well differentiated but abnormal ganglion cells that are neither primitive neuroblasts nor the small round neurons of neurocytomas. The presence of numerous dense core vesicles and tyrosine hydroxylase in neuronal component, mainly disclosed with electron microscopy<sup>(8)</sup>, suggests that the probable origin of these cells could be ectopic neural crest tissue.

The treatment of choice is surgery and gross total resection is the best chance for cure<sup>(5)</sup>. Long term survival is achieved if gross total resection is possible, ranging between 7 and 17 years. However, gangliogliomas with components located in the brain stem and optic tracts are usually known to be managed by subtotal resections, which carry a greater chance for recurrence<sup>(6)</sup>. Adjuvant treatment, such as postoperative radiotherapy, has been noted in several studies not to be beneficial for patients with WHO Grade 1 or 2 tumors. Luyken et al. recently reported that 27% of atypical and 50% of anaplastic GG patients in their series had local recurrence without adjuvant local treatment. Although there is no clear consensus in the literature for adjuvant radiotherapy.

Although routine adjuvant radiotherapy is not indicated after total resection<sup>(9)</sup>, patients with recurrent tumors or tumors with anaplastic component are commonly referred to radiotherapy. Radiotherapy may also be indicated in subtotally resected tumors in order to improve local control rates. As Kitano et al.<sup>(10)</sup> documented relapse after radiotherapy with doses as low as 30 Gy, doses greater than 50 Gy is frequently

recommended for local control<sup>(10)</sup>. Unfortunately, higher doses could still not guarantee tumor control<sup>(9)</sup>.

We prescribed a dose of 54 Gy in conventional fractions to treat our patient with conformal radiotherapy and have not experienced a local failure yet. Some authors raised the possibility that radiation therapy in patients with initial benign histologies may predispose to malignant degeneration<sup>(9)</sup>, while some authors noted that radiotherapy does not result in malignant degeneration. Though there is no current consensus on adjuvant chemotherapy in ganglioglioma cases, Silver et al.<sup>(5)</sup> demonstrated no substantial benefit of chemotherapy.

### Conclusion

Ganglioglioma is a rare entity but differential diagnosis should be kept in mind especially in children with circumscribed tumour on radiology. Gross total resection is treatment of choice and adjuvant therapy can be offered in which there is a residual tumour or recurrence or progression to anaplastic glioma.

### References

1. Courville C: Tumor of the central nervous system: review of the literature and report of two cases. *Arch Neurol Psychiatry* 24: 439-491,1930.
2. Peretti-Viton P et al.: Magnetic resonance imaging in gangliogliomas and gangliocytomas of the nervous system. *J Neuroradiol* 18(2): 189-199,1991.
3. Kalyan-Raman UP, Olivero WC: Ganglioglioma: a correlative clinicopathological and radiological study of ten surgically treated cases with follow-up. *Neurosurgery* 20(3):428-433,1987.
4. Benitez WI et al.: MR findings in childhood gangliogliomas. *J Comput Assist Tomogr* 14(5):712-716,1990.
5. Silver JM et al.: Ganglioglioma: a clinical study with long-term follow-up. *Surg Neurol* 35(4):261-266,1991.
6. Haddad SF et al.: Ganglioglioma: 13 years of experience. *Neurosurgery* 31(2):171-178,1992.
7. Allegranza A et al.: Cerebral ganglioglioma with anaplastic oligodendroglial component. *Histopathology* 17(5):439-441,1990.
8. Rubinstein L J, Herman M M: A light-and electron-microscopic study of a temporal-lobe ganglioglioma. *J Neurol Sci* 16(1):27-48,1972.
9. Selch MT et al.: Gangliogliomas: experience with 34 patients and review of the literature. *Am J Clin Oncol* 21(6):557-564,1998.
10. Kitano M et al.: Malignant ganglioglioma of the spinal cord. *Acta Pathol Jpn* 37(6):1009-1018,1987.