

## Focal cortical dysplasia: a case report and review

Pramod Kumar Berwal<sup>1</sup>, Chhavi Souparna<sup>2</sup>, Niranjan Nagaraj<sup>3,\*</sup>, Tara Chand Saini<sup>4</sup>

<sup>1</sup>Professor & Head, <sup>2</sup>Junior Resident, <sup>3</sup>Senior Resident, <sup>4</sup>Junior Specialist, Dept. of Paediatrics, Sardar Patel Medical College, Rajasthan

**\*Corresponding Author:**

**Niranjan Nagaraj**

Senior Resident, Dept. of Paediatrics, Sardar Patel Medical College, Rajasthan

Email: getniranjan806@yahoo.com

### Abstract

Focal cortical dysplasia (FCDs) are increasingly diagnosed as a cause of symptomatic focal epilepsy in pediatric patients. A 7-year-old boy presented with intractable partial epilepsy since 3 years. Electroencephalography (EEG) shows no abnormality. Magnetic resonance imaging (MRI) of Brain revealed mild thickening of cortex with loss of gyral pattern in left temporal region, Possibility of focal cortical deficit. Patient follow up was done for 1 year. Seizure was controlled with two anticonvulsant like sodium valproate and phenytoin.

**Keywords:** Seizure, Focal cortical dysplasia, MRI, Anti convulsant.

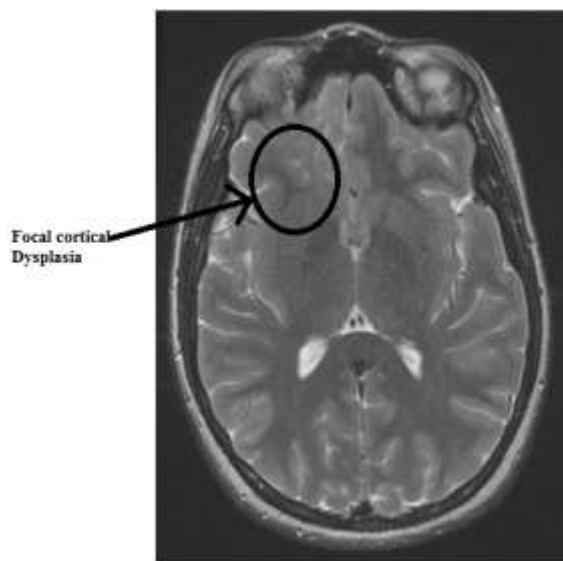
### Introduction

Malformations of cortical development are a frequent cause of symptomatic focal epilepsy in childhood and adulthood. In particular, focal cortical dysplasia (FCD) is increasingly recognized in epilepsy patients owing to improved MRI techniques.<sup>1</sup> Focal cortical dysplasia is a rare cause of intractable partial epilepsy.<sup>2</sup> Focal cortical dysplasia represents a heterogeneous group of disorders of cortical malformation resulting from aberrant patterns of brain development. In this, during natural development neurons fail to spread outward to cerebral cortex and position correctly, so signals will misfire triggering a seizure. It is highly correlated with childhood seizure syndrome as well as with cognitive disabilities and other neurological disorders. Only few studies have so far focused their interest on clinical features in patients with FCD. There is only less knowledge of the course of the disease. We report a case of focal intractable epilepsy with MRI suggestive of focal cortical dysplasia.

### Case Report

A 7-year-old boy presented with intractable partial epilepsy since 3 years. The Antenatal and perinatal history was normal. No cutaneous or systemic abnormalities. The first seizure occurred in the 4.5 years of life consisting of partial unilateral-clonic movement of right upper limb with up rolling of eye balls, clenching of teeth, frothing from mouth, right head deviation and post ictal drowsiness for 15 minutes. This fits was present for 8-10 minutes. Patient was taken peripheral health Centre. General physical examination and systemic examination was normal. No cutaneous abnormality was present. Patient was started on anticonvulsant with sodium valproate and maintenance daily dose was advised. No investigations

were done and discharged patient from hospital. At 6 year patient had similar complaints, the anticonvulsant sodium valproate dose was increased. Patient was evaluated with basic investigations. Electroencephalography (EEG) revealed no abnormality. Magnetic resonance imaging (MRI) of Brain revealed mild thickening of cortex with loss of gyral pattern in left temporal region, Possibility of focal cortical deficit. Patient was referred to higher centre for surgery. Patient attenders refused for surgery. Patient follow up was done for 1 year. Seizure was controlled with two anticonvulsant like sodium valproate and phenytoin.



**Fig. 1:** Axial T2-weighted image showing patchy irregular T2 prolongation in the inferior right frontal cortex with associated abnormal Gyral pattern and white matter, consistent with focal cortical dysplasia

## Discussion

Focal cortical dysplasia refers to the malformations of cortical development, which may result from perturbations of neuron proliferation and/or cortical organization.<sup>(3)</sup> Focal cortical dysplasia is classified into three types as: Type I: architectural abnormalities, Type II (Taylor type): architectural abnormalities and dysplastic neurons IIa: without balloon cells IIb: with balloon cells. Malformations of cortical development reflect embryological disruptions in: Neuronal proliferation (ex. TSC), Neuronal migration (ex. heterotopias), Cortical organization (ex. schizencephaly), Multiple steps (ex. focal cortical dysplasia) 2. These lesions are important causes of refractory epilepsy.<sup>(4)</sup> In our case report EEG was normal; it shows EEG is not preferred tool for investigation. MRI findings of our study were similar with other studies.<sup>(5)</sup> MRI is the investigative choice for malformations of cortical development. More information available from newer sequences and different MR modalities. Neuroimaging of these lesions is important for diagnosis and management decisions in epilepsy, including the feasibility and likely success of surgical resection in cases that are refractory to medication. In this case seizure was controlled by two anticonvulsants.

## Bibliography

1. Fauser S, Huppertz HJ, Bast T, Strobl K, Pantazis G, Altenmueller DM, Feil B. Clinical characteristics in focal cortical dysplasia: a retrospective evaluation in a series of 120 patients. *Brain* 2006;129:1907–1916.
2. Saint Martin C, Adamsbaum C, Robain O, Chiron C, Kalifa G. An Unusual Presentation of Focal Cortical Dysplasia. *AJNR* 1995;16:840–842.
3. Chiang KL, Wong TT, Kwan SY, Hsu TR, Wang CH, Chang HP. Finding on brain MRI mimicking focal cortical dysplasia in early Rasmussen's encephalitis: a case report and review. *Childs Nerv Syst* 2009;23:5-9.
4. Widdess-Walsh P, Diehl B, Najm I. Neuroimaging of focal cortical dysplasia. *J Neuroimaging* 2006;16:185-196.
5. Luat AF, Makki M, Chugani HT. Neuroimaging in tuberous sclerosis complex. *Curr Op in Neurology* 2007;20:142-150.