



## Short Communication

## Story of an acute stroke and dual central nervous system infection

Debabrata Chakraborty<sup>1\*</sup>, Enakshi Debnath<sup>2</sup><sup>1</sup>Dept. of Neurology, Apollo Multispeciality Hospitals, Kolkata, West Bengal, India<sup>2</sup>Dept. of Emergency, Apollo Multispeciality Hospitals, Kolkata, West Bengal, India

## ARTICLE INFO

## Article history:

Received 09-04-2024

Accepted 18-06-2024

Available online 27-06-2024

This is an Open Access (OA) journal, and articles are distributed under the terms of the [Creative Commons Attribution-NonCommercial-ShareAlike 4.0 License](#), which allows others to remix, tweak, and build upon the work non-commercially, as long as appropriate credit is given and the new creations are licensed under the identical terms.

For reprints contact: [reprint@ipinnovative.com](mailto:reprint@ipinnovative.com)

A 30-year-old man with no background medical illness had a history of intermittent fever for three weeks. He was treated for an upper respiratory tract infection and the intensity of fever subsided. One day, he had a sudden onset weakness of the right upper and lower limb along with speech impairment and was rushed to the emergency room within one hour. His vitals were stable and NIHSS (National Institutes of Health Stroke Scale) was 12. CT scan revealed multiple hyper densities (possibly calcifications) in the bilateral frontal, occipital, and left cerebellar hemispheres with hypo density in the left internal capsule. Given multiple calcific lesions on the background of fever, thrombolysis was not done, and we proceeded for an MRI of the brain with contrast for specification of the lesions. MRI of the brain revealed acute to subacute infarcts in left para ventricular white matter, centrum semi-ovale, left thalamus, left ganglion-capsular area; multiple ring-enhancing lesions in cerebellar, cerebral hemispheres, along with leptomeningitis. [Figure 1]

The cerebrospinal picture revealed: a cell counts of 265/ cubic milimetre (lymphocytic predominance), elevated protein (181 mg%), and glucose of 14 mg/dl. The comprehensive infection panel of the cerebrospinal fluid revealed streptococcus pneumoniae. We treated the patient with antitubercular drugs (as per body weight) and high-dose steroids (to deal with the meningitis and vasculitis

part). We had a high clinical suspicion of CNS tuberculosis, although TB-Gene X-pert came out to be negative. The PCR and (later) culture-positive streptococcus pneumoniae were also treated with ceftriaxone for two weeks.

Concurrent central nervous system infections involving tuberculosis and streptococcal infection have been rarely documented but involved immunosuppressive conditions like sickle cell disease, diabetes, and prematurity.<sup>1</sup>

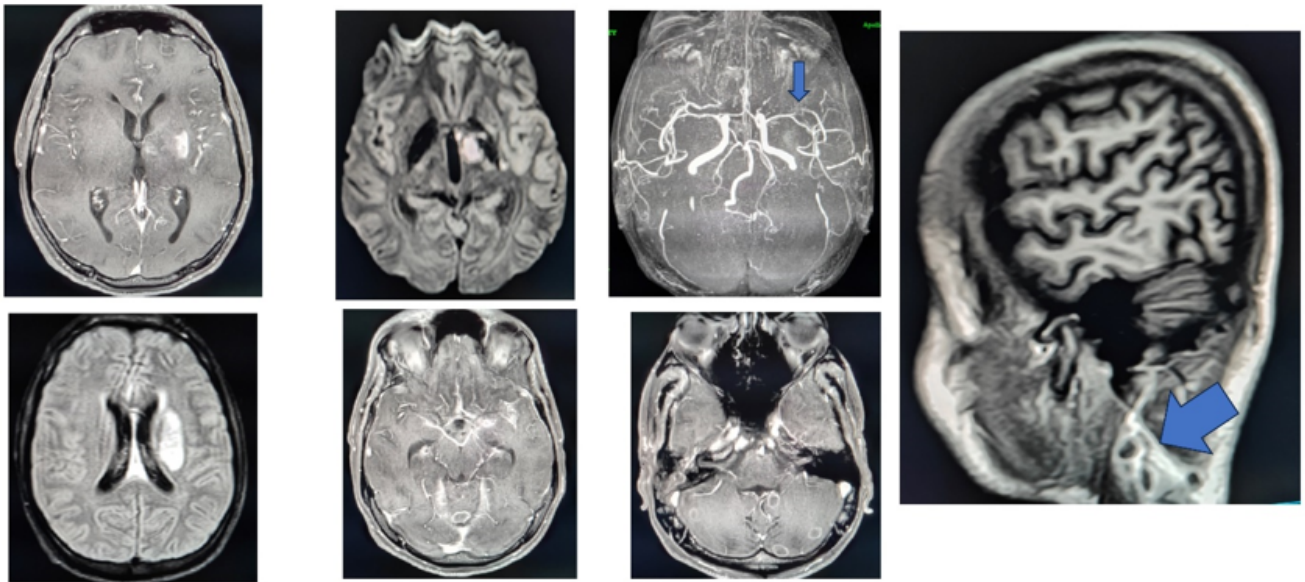
However, our patient was a young immunocompetent host with no co-morbidity, this makes our case more interesting. He must have an altered immunological state which promoted hosting of these two life-threatening central nervous system infections. In future, we need further research to identify these special group of patients and provide them with special vaccines or immunity boosters to prevent and tackle these situations more confidently.

We need also to remember that there are few pitfalls and these tests are not absolute, rather they should be matched with clinical findings. The sensitivity of culture and PCR for clinically relevant meningitis was 43% and 59% respectively, while the specificity associated with both these modalities was 97%.<sup>2</sup>

A few factors contribute to discordant results between cerebrospinal fluid bio-fire and clinical disease. They are probably specimen contamination, testing for patients with low pretest probability, testing after empiric antimicrobial therapy, traumatic lumbar puncture, and organism-specific factors.<sup>3</sup>

\* Corresponding author.

E-mail address: [drdchakraborty1980@gmail.com](mailto:drdchakraborty1980@gmail.com) (D. Chakraborty).



**Figure 1:** MRI of the brain with contrast revealed acute to subacute infarcts in left para ventricular white matter, centrum semi-ovale, left thalamus, left ganglio-capsular area; multiple ring-enhancing lesions in cerebellar, cerebral hemispheres, along with leptomenigitis. MR Angiogram showed left M2 division of middle cerebral artery occlusion (blue arrow) and cervical lymph nodes (thicker blue arrow)

Similarly, the sensitivity of TB Gene X-pert was found to be 59.3% and specificity to be 99.5%; the negative predictive value of the test was found to be 72.5%.<sup>4</sup>

Thus, in developing countries like India where the prevalence of tuberculosis is high, we need to be more clinic-based and the families of the patients also need to understand the importance of antitubercular drugs in this type of clinical scenario. This is important as in unfortunate circumstances tubercular drug-related side effects may have medicolegal implications, especially when we have offered empiric antitubercular drugs in these patients.

Another interesting move in our case was the decision for thrombolysis or endovascular therapy in this young man who came with acute stroke. Thrombolysis in infective vasculitis is often detrimental as the haemorrhagic conversion rate is high.<sup>5</sup> So, we rightfully cancelled any such venture. As there was no significant DWI - FLAIR mismatch, we did not proceed with mechanical thrombectomy in our patient. We should be cautious and move a step back in any acute stroke intervention when such a history comes up in the picture.

Our patient had infective vasculitis and related stroke. Intracranial vasculopathy is an important complication of bacterial meningitis and increases the risk of stroke. It affects in 37.1% of patients with bacterial meningitis and may be secondary to vasculitis related vasospasm, endocarditis or intra-arterial thrombosis.<sup>6</sup> It is usually associated with poor prognosis. Stroke in tuberculous meningitis was found in 15-57% of patients and were noted mainly in advance stage or in case of severe illness.<sup>7</sup> Most of the strokes in tubercular meningitis were bilateral,

multiple and in the 'tubercular zone' which comprises the anterior limb, genu of the internal capsule anterior thalamus and caudate.<sup>7</sup> Our patient though had dual central nervous system infection and stroke (both streptococcus pneumoniae and tuberculosis might be the culprit); he had stroke at the classical "tubercular zone".

The patient has attended our outpatient department for follow-up after one and a half months. He has regained considerable speech, though still having mild expressive aphasia; the power of the right side has improved from 1/5 (MRC scale) to 3/5, and he is under regular rehabilitation. He has no drug-related adverse reactions or disease related complications.

### Conflict of Interest


None.

### References

1. Levinsky RJ, Wilkinson A. Mixed pneumococcal and tuberculous meningitis. *Arch Dis Child.* 1974;49(4):325–8.
2. Welinder-Olsson C, Dotevall L, Hogevik H, Jungnelius R, Trollfors B, Wahl M, et al. Comparison of broad-range bacterial PCR and culture of cerebrospinal fluid for diagnosis of community-acquired bacterial meningitis. *Clin Microbiol Infect.* 2007;13(9):879–86.
3. Waldrop G, Zucker J, Boubour A, Radmard S, Green DA, Thakur KT, et al. Clinical Significance of Positive Results of the BioFire Cerebrospinal Fluid FilmArray Meningitis/Encephalitis Panel at a Tertiary Medical Center in the United States. *Arch Pathol Lab Med.* 2022;146(2):194–200.
4. Nhu NT, Heemskerck D, Thu D, Chau TT, Mai NT, Nghia HD, et al. Evaluation of GeneXpert MTB/RIF for diagnosis of tuberculous meningitis. *J Clin Microbiol.* 2014;52(1):226–33.

5. Fattahi P, Sheriff F, Narayanan NS, Greer DM, Schindler J. Thrombolysis for acute stroke in patients with vasculitis: case report and literature discussion. *Clin Neurol Neurosurg.* 2013;115(3):351–3.
6. Idris MI, Tai SML, Tan CT, Tan KS. Streptococcus pneumoniae Meningitis and Intracranial Vasculopathy: Clinical Correlation with Improving Transcranial Doppler Hemodynamics. *Case Rep Neurol.* 2020;12(1):106–9.
7. Misra UK, Kalita J, Maurya PK. Stroke in tuberculous meningitis. *J Neurol Sci.* 2011;303(1-2):22–30.

### Author biography

**Debabrata Chakraborty**, Senior Consultant  <https://orcid.org/0000-0003-1867-6116>

**Enakshi Debnath**, Consultant

**Cite this article:** Chakraborty D, Debnath E. Story of an acute stroke and dual central nervous system infection. *IP Indian J Neurosci* 2024;10(2):119-121.